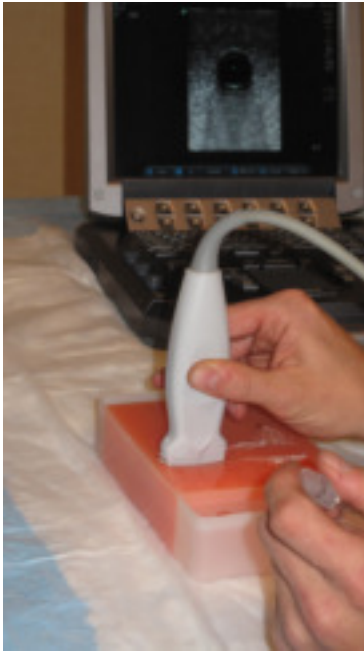


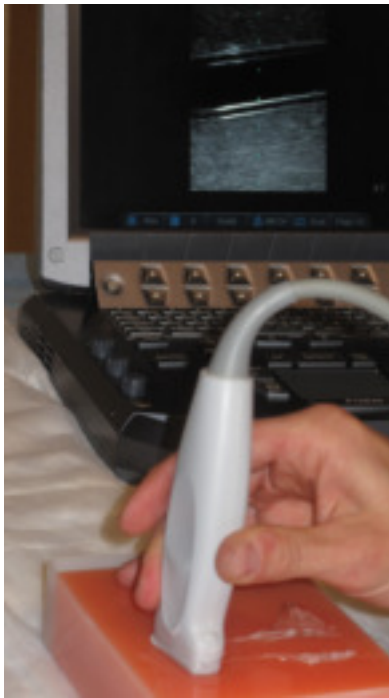Ultrasound Guided Vascular Access: Vascular Block



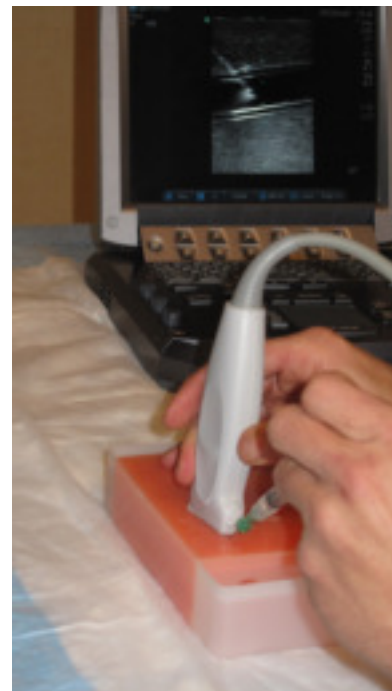
Out of Plane View of Vessel



Cannulate vein under direct visualization: out of plane



In Plane View of Vessel



Cannulate vein under direct visualization: in plane

