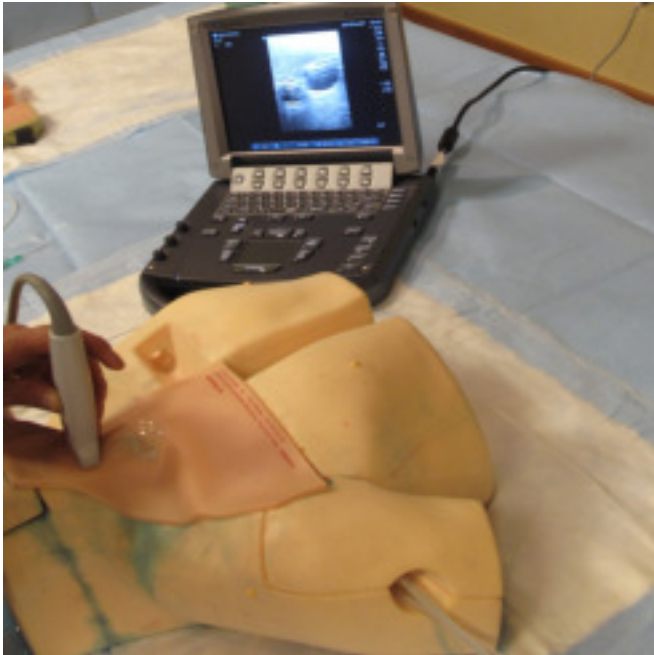
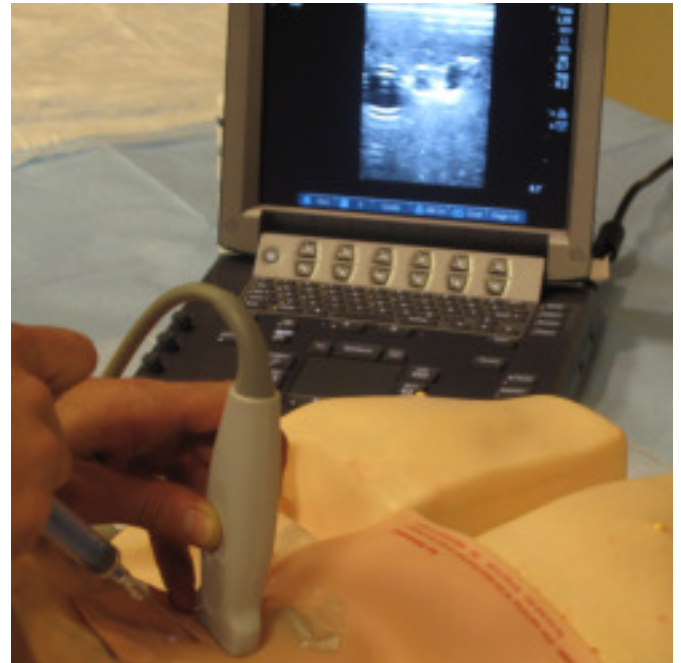

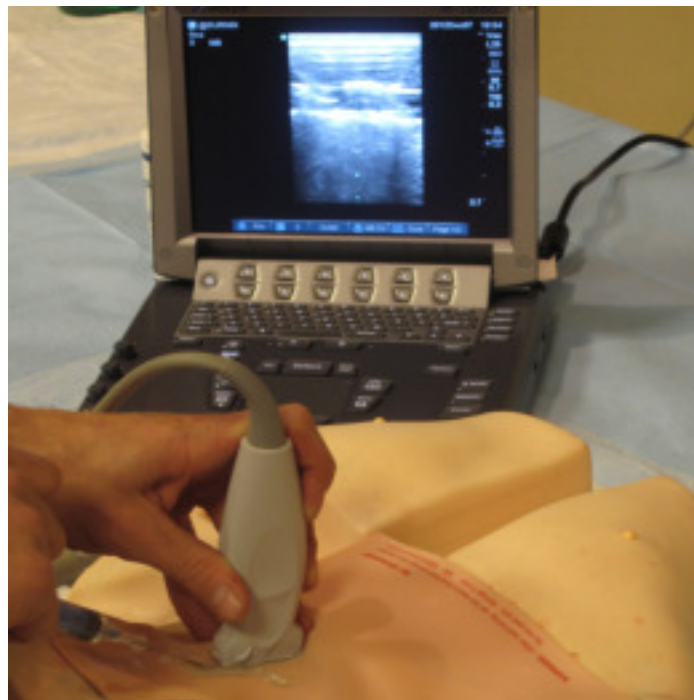Ultrasound Guided Central Line Placement



Step 1: Palpate landmarks and place ultrasound probe near apex of anterior cervical triangle: Out of plane view



Step 2: Out of plane approach: Use introducer needle to puncture skin behind ultrasound probe with needle angled to enter vessel directly under probe



In plane approach: Needle is positioned directly behind ultrasound probe and is advanced parallel to probe under skin

