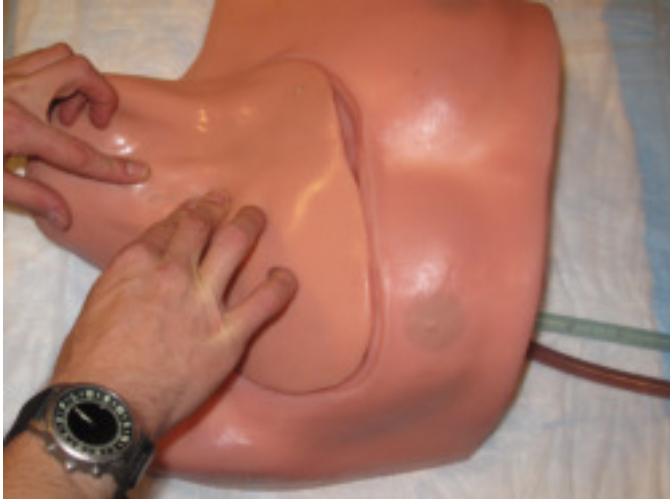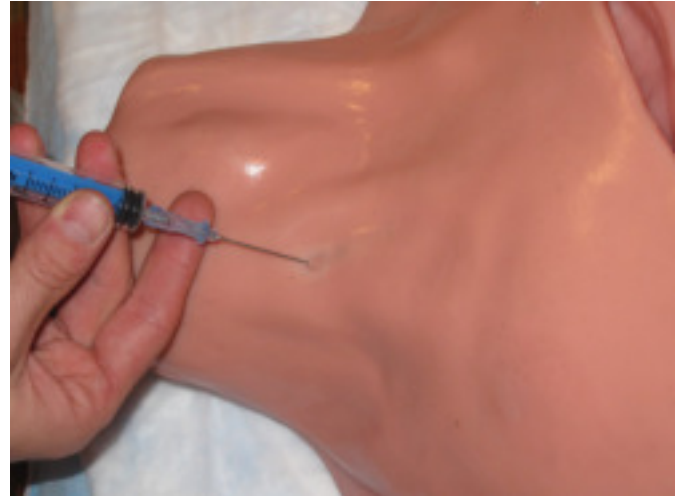


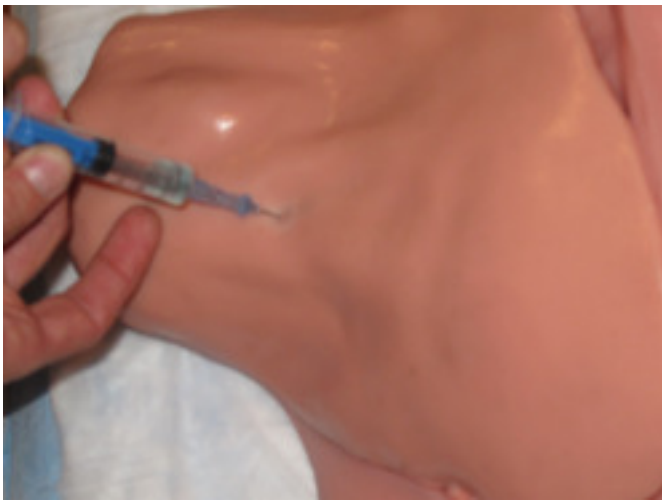Landmark Based Internal Jugular Catheter Placement



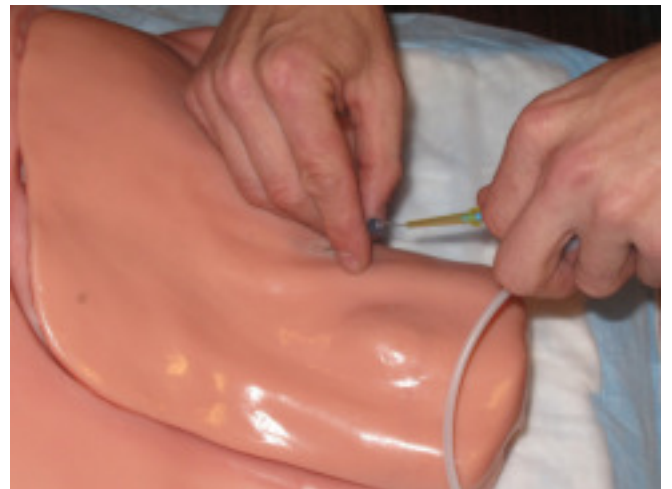Step 1: Palpate landmarks: Anterior cervical triangle formed by clavicle and two heads of sternocleidomastoid muscle



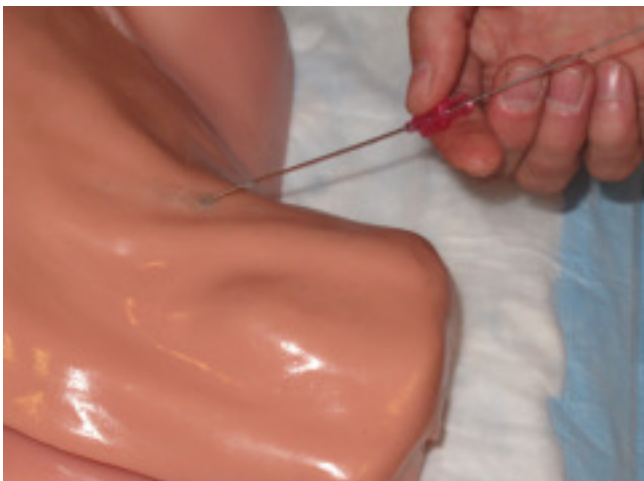Step 2: Use introducer needle to puncture skin near apex of triangle and direct needle at 30 degrees to skin toward ipsilateral nipple



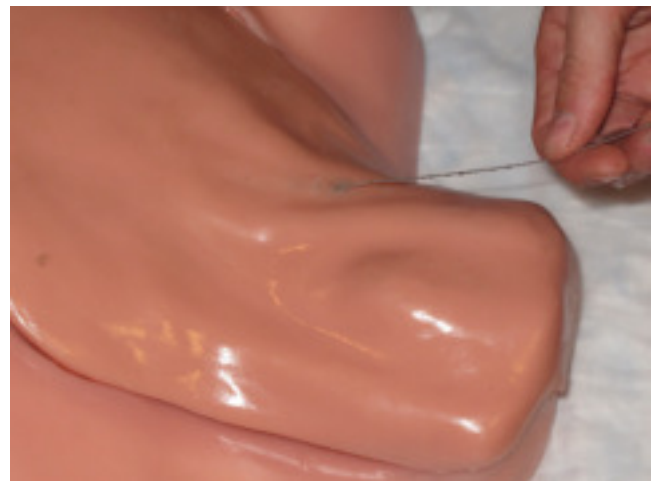Step 3: Advance needle 2 to 3 cm until flash of blood from internal jugular vein seen in syringe



Step 4: Remove syringe, confirm nonpulsatile blood flow from needle, and advance guidewire through needle into vein



Step 5: Remove needle over guidewire



Procedure Complete!

